

Research Article

Open Access

Study of Morphological Variations of Vermiform Appendix and Caecum in Cadavers of Western Maharashtra Region

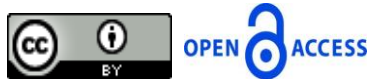Nilesh Ashok Salwe, P.G. Kulkarni and R.S. Sinha

Department of Anatomy, Grant Government Medical College, Byculla, Mumbai, Maharashtra, India

Correspondence should be addressed to Nilesh Ashok Salwe, nilesh.salwe@rediffmail.com

Publication Date: 26 September 2014

Article Link: <http://medical.cloud-journals.com/index.php/IJAPAS/article/view/Med-177>



Copyright © 2014 Nilesh Ashok Salwe, P.G. Kulkarni and R.S. Sinha. This is an open access article distributed under the **Creative Commons Attribution License**, which permits unrestricted use, distribution, and reproduction in any medium, provided the original work is properly cited.

Abstract Aim was to study morphological variations of vermiform appendix and caecum. 60 embalmed donated cadavers (30 male and 30 female) were dissected to study morphological variations of vermiform appendix and caecum in the department of Anatomy of Grant Government Medical College, Byculla, Mumbai, India. Position, length, outer girth of appendix, distance of appendix from ileocaecal junction, shape, length and width of caecum were studied. Sex differences and relation between shape of caecum and position of appendix were studied. Photographs were taken for proper documentation. Most common position of vermiform appendix was retrocaecal 56.67% then pelvic 25%, preileal 15% and postileal 3.33%. In males it was retrocaecal 23.33% then pelvic 15%, preileal 8.33% and postileal 3.33%. In females it was retrocaecal 33.33% then pelvic 10%, preileal 6.67%. Average length of appendix was 5.93 cm. In males it was 6.30 cm and in females it was 5.55 cm. Average outer girth of appendix was 2.80 cm. In males it was 2.83 cm and in females it was 2.76 cm. Average distance of appendix from ileocaecal junction was 2.47 cm. In males it was 2.63 cm and in females it was 2.31 cm. Most common shape of caecum was adult 73.33%, exaggerated 13.33%, infantile 8.33%, fetal 5%. In males it was adult 33.33%, exaggerated 10%, infantile 3.33%, and fetal 3.33%. In females it was adult 40%, exaggerated 3.33%, infantile 5% and fetal 1.67%. Average length of caecum was 7.52 cm. In males it was 8.07 cm and in females it was 6.97 cm. Average width of caecum was 8.48 cm. In males it was 9.05 cm and in females it was 7.92 cm. Out of total retrocaecal appendix 76.5% were with adult caecum, 11.8% were with exaggerated caecum, 8.8% were with infantile caecum, 2.9% were with fetal caecum. Out of total pelvic appendix 73.3% were with adult caecum, 13.3% were with infantile caecum, 13.3% were with fetal caecum and none of them were exaggerated. Out of total preileal appendix 55.6% were with adult caecum, 44.6% were with exaggerated caecum and none of them were fetal and infantile. Out of total postileal appendix 100% were with adult caecum and none of them were exaggerated, infantile or fetal. The knowledge of anatomy of vermiform appendix and caecum is of significant importance during surgical and radiological procedure to avoid any catastrophical complication.

Keywords *Pelvic; Postileal; Preileal; Retrocaecal*

1. Introduction

The vermiform appendix was first described by Leonardo da Vinci in 1492 [1]. Appendix is a worm like tubular vestigial structure situated in right iliac fossa. Appendicitis is the most common cause of acute abdomen in young people. At present, appendectomy for appendicitis is the most commonly performed emergency operation in the world. Rate of appendectomy is 12% for men and 25% for women, with approximately 7% of all people undergoing appendectomy for acute appendicitis during their lifetime [2].

Anatomically, the position of the appendix can vary with respect to the caecum and can be retrocaecal, paracolic, preileal, postileal, pelvic or subcaecal [4]. Identification of the normal position of appendix is important because in appendicitis variable positions may produce symptoms and signs related to position and hence can mimic other diseases. Hence knowledge of these variations is essential for accurate diagnosis and treatment of the condition [3].

A retrocaecal appendix may lie behind a caecum distended with gas and thus it may be difficult to elicit tenderness on palpation in the right iliac region. Irritation of the psoas muscle conversely may cause the patient to keep the right hip joint flexed (psoas sign). An appendix hanging down in the pelvis may result in absent abdominal tenderness in the right lower quadrant but deep tenderness may be experienced just above the pubic symphysis. In pelvic appendicitis, diarrhea results from an inflamed appendix being in contact with rectum. Rectal or vaginal examination may reveal tenderness of the peritoneum in the pelvis on the right side. An inflamed appendix when it is in contact with the urinary bladder may cause increased frequency of micturition. If such an inflamed appendix perforates, a localized pelvic peritonitis may result. Long retro-colic inflamed appendix also called sub hepatic appendix and it causes confusion with cholecystitis. In retrocaecal and retrocolic variety of appendix, the chances of gangrenous complication are more because in these cases blood vessels get kinked. In preileal position appendix directs towards the spleen and if it becomes inflamed it is liable to result in general peritonitis and is the most dangerous position. Postileal appendix called missed appendix is common in children and in early adult life. Postileal inflamed appendix may cause diarrhea. Perforation of the appendix or transmigration of bacteria through the inflamed appendicular wall results in infection of the peritoneum of the greater sac. Inflammation of atypically located vermiform appendix may initiate inflammation of other organs which leads to diagnostic errors and life threatening complications [5].

With this rationale in mind, this study has been undertaken to investigate certain anatomical features and different positions of the vermiform appendix and caecum in cadavers of Western Maharashtra region.

2. Materials and Methods

- 1) Cadavers allotted to MBBS students were selected from medical colleges in the Western Maharashtra region. Both male and female cadavers were included in the study. Each cadaver was dissected by making a midline incision on the abdomen and reflecting the flaps.
- 2) The vermiform appendix was located by following the anterior taenia coli and its position was determined. Based on position, the appendix was categorized into retrocaecal, pelvic, preileal, postileal, paracolic, subcaecal and paracaecal groups. Photographs were taken of cadaveric appendix specimens.
- 3) The length of the appendix from the base to the tip was measured with the help of thread. Thread's length was measured by measuring scale and the values were recorded.

- 4) Outer girth of appendix was measured with the help of thread at the midpoint of the appendix and thread's length was measured by measuring scale and the values were recorded.
- 5) Distance of the appendix from ileocaecal junction was measured between the lower border of the terminal part of ileum and the base of the appendix where taenia coli end. The distance was measured with the help of thread and thread's length was measured by measuring scale and values were recorded.
- 6) Based on shape, the caecum was categorized into fetal, infantile, adult, exaggerated groups and photographs of caecum specimens were taken.
- 7) Length of a caecum was measured from a horizontal line at the level of the ileocaecal orifice to its lowest point with the help of thread and thread's length was measured by measuring scale and values were recorded.
- 8) Width of caecum was measured with the help of thread at the midpoint of the caecum and thread's length was measured by measuring scale and values were recorded.

3. Results and Discussion

There are various studies done on positions and dimensions of vermiform appendix and caecum all over the world such as Golalipur et al. (2003) in Iran, Katzurskj et al. (1979) in Zambia, Solanke T.F. (1970) in Nigeria. But there are few studies in India like Ajmani M.L. and Ajmani K. (1983) in Uttar Pradesh region; Geethanjali H.T. and Lakshmi Prabha Subhash (2012) in Karnataka region on this subject and there are very few studies in Western Maharashtra region. So we have studied different positions and dimensions of vermiform appendix and different shapes and dimensions of caecum in cadavers allotted to MBBS students of medical colleges in the Western Maharashtra region.

3.1. Position of Vermiform Appendix

Table 1: Comparison of Different Positions of the Vermiform Appendix of Present Study with Other Studies

Author, Year, Number of Specimens	Percentage Occurrence of Various Positions					
	Retrocaecal	Pelvic	Postileal	Preileal	Sub-Caecal	Right Paracaecal
Wakely [14], 1933, 10000.	62%	31%	0.4%	1%	2%	-
Shah and Shah [27], 1942, 59151.	4%	16.6%	15.8%	11.7%	4.7%	-
Solanke T.F. [8], 1970, 125.	38.4%	31.2%	4%	12%	11.2%	2.4%
Golalipur M.J. [4], 2003, 117.	32.4%	33.3%	2.6%	18.8%	12.8%	-
Present study	56.67%	25%	3.33%	15%	-	-

According to Hollinshead H.W., percentage occurrence of various positions of vermiform appendix are as follows retrocaecal and retrocolic (65.28%), pelvic (31.01%), subcaecal (2.26%), preileal (1%), postileal (0.4%) and vermiform appendix associated with an ectopically placed caecum (0.05%) [31].

In the Present Study it was found that

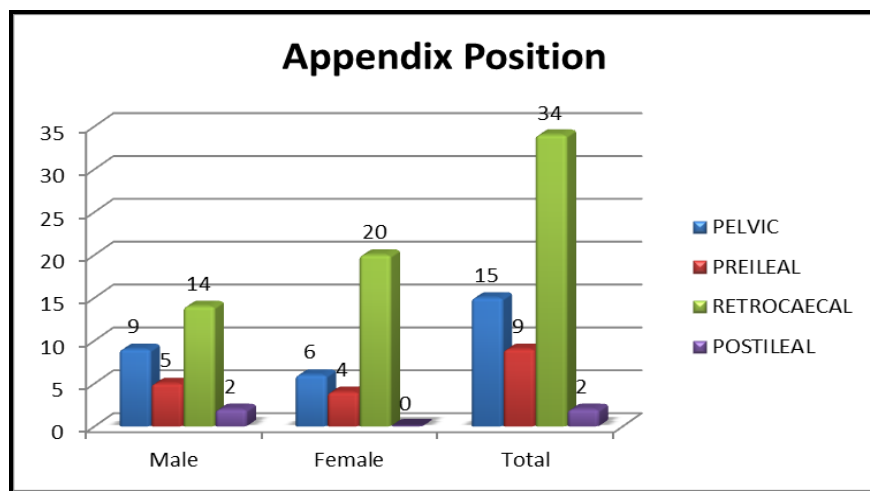
Most common position of vermiform appendix was retrocaecal 56.67% then pelvic 25%, preileal 15% and postileal 3.33%. In males it was retrocaecal 23.33% then pelvic 15%, preileal 8.33% and postileal 3.33%. In females it was retrocaecal 33.33% then pelvic 10%, preileal 6.67%.

Thus, in the present study the position of appendix was comparable to the study conducted by previous authors. This study also shows that the comparison of position of vermiform appendix between male and female was statistically not significant (p value= 0.28).

Table 2: Position of Appendix in Male and Female

Appendix Position	Male	%	Female	%	Total	%
PELVIC	9	15.00	6	10.00	15	25.00
PREILEAL	5	8.33	4	6.67	9	15.00
RETROCAECAL	14	23.33	20	33.33	34	56.67
POSTILEAL	2	3.33	0	0.00	2	3.33

p - Value = 0.28



Graph 1: Position of Vermiform Appendix

3.3. Length of Vermiform Appendix

Table 3: Comparison of Length of the Vermiform Appendix of Present Study with Other Studies

Author, Year	Shortest (cm)	Longest (cm)	Average (cm)
Monks & Blake, 1902	1.0	24.0	7.9
Deaver, 1913	1.0	23.0	8.9
Lewis, 1918	2.0	20.0	8.3
Robinson [49], 1923	1.8	23.0	9.2
Royster, 1927	2.5	20.0	7.5
Hafferl, 1953	2.5	20.0	9.0
Present study	2.8	12	5.93

Length of the vermiform appendix varies from 2 cm to 20 cm, with an average length of 9 cm [10]. Ajmani and Ajmani (1983) found average length of the appendix as 9.5 cm in male and 8.7 cm in female [33]. The appendix is lined by columnar epithelium [10].

In the Present Study it was found that

Average length of appendix was 5.93 cm with range from 2.8 cm to 12 cm. Average length of appendix in males was 6.30 cm with range from 2.8 cm to 12 cm and in females was 5.55 cm with range from 3 cm to 10.3 cm.

Thus, in the present study length of vermiform appendix was comparable to the study conducted by previous authors.

3.4. Outer Girth of Vermiform Appendix

Outer girth of vermiform appendix varies from 2 cm to 3 cm, with an average length of 2.8 cm [8].

In the Present Study it was found that

Average outer girth of appendix was 2.8 cm with range from 1.4 cm to 5.3 cm. Average outer girth of appendix in males was 2.83 cm with range from 1.4 cm to 4 cm and in females was 2.76 cm with range from 1.6 cm to 5.3 cm.

Thus, in the present study outer girth of appendix was comparable to the study conducted by previous authors.

3.5. Distance of Vermiform Appendix from Ileocaecal Junction

Distance of vermiform appendix from the ileocaecal junction varies from 2 cm - 3 cm, with an average of 2.5 cm [11]. The origin of appendix is about 2.5 cm below the ileocaecal valve from the posteromedial aspect of caecum [6].

In the Present Study it was found that

Average Distance of appendix from ileocaecal junction was 2.47 cm with range from 1 cm to 4.1 cm. Average Distance of appendix from ileocaecal junction in male was 2.63 cm with range from 1 cm to 3.9 cm and in female was 2.31 cm with range from 1.2 cm to 4.1 cm.

Thus, in the present study distance of vermiform appendix from the ileocaecal junction was comparable to the study conducted by previous authors.

3.6. Shape of Caecum

Most common shape of caecum is adult 90%, exaggerated 4%, infantile 3%, fetal 3% [7].

In the Present Study it was found that

Most common shape of caecum was adult 73.33%, exaggerated 13.33%, infantile 8.33%, fetal 5%. In males most common shape of caecum was adult 33.33%, exaggerated 10%, infantile 3.33%, and fetal 3.33%. In female most common shape of caecum is adult 40%, exaggerated 3.33%, infantile 5% and fetal 1.67%.

Thus, in the present study the shape of caecum was comparable to the study conducted by previous authors. This study also shows that the comparison of shape of caecum between male and female was statistically not significant (p value= 0.41).

Table 4: Shape of Caecum in Male and Female

Caecum Shape	Male	%	Female	%	Total	%
ADULT	20	33.33	24	40.0	44	73.33
EXAGGERATED	6	10.00	2	3.33	8	13.33
FETAL	2	3.33	1	1.67	3	5.00
INFANTILE	2	3.33	3	5.0	5	8.33
Total	30	50.00	30	50.0	60	100

3.7. Length of Caecum

Average axial length of caecum is about 6 cm [7].

In the Present Study it was found that

Average length of caecum was 7.52 cm with range from 5 cm to 10.6 cm. Average length of caecum in males was 8.07 cm with range from 6.1 cm to 10.6 cm and in females was 6.97 cm with range from 5 cm to 10.2 cm.

Thus, in the present study length of caecum was comparable to the study conducted by previous authors.

3.8. Width of Caecum

Average axial width of caecum is about 7.5 cm [7].

In Present Study it was found that

Average width of caecum was 8.48 cm with range from 6 cm to 12.5 cm. Average width of caecum in males was 9.05 cm with range from 6.8 cm to 12.5 cm and in females was 7.92 cm with range from 6 cm to 11.8 cm.

Thus, in the present study width of caecum was comparable to the study conducted by previous authors.

3.9. Relation between Position of Vermiform Appendix and Shape of Caecum

Jorge A., Ferreira J.R. and Pacheco Y.G. (2009), reported that in all positions of appendix most common shape of caecum is adult [37].

In Present Study it was found that

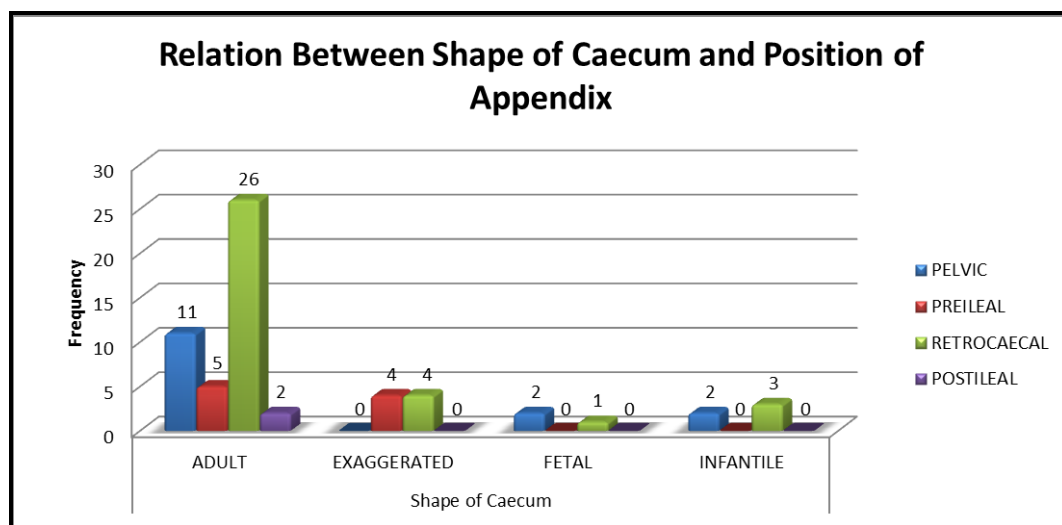
Out of total retrocaecal appendix 76.5% were with adult caecum, 11.8% were with exaggerated caecum, 8.8% were with infantile caecum, 2.9% were with fetal caecum. Out of total pelvic appendix 73.3% were with adult caecum, 13.3% were with infantile caecum, 13.3% were with fetal caecum and none of them were exaggerated. Out of total preileal appendix 55.6% were with adult caecum, 44.6% were with exaggerated caecum and none of them were fetal and infantile. Out of total postileal appendix 100% were with adult caecum and none of them were exaggerated, infantile or fetal.

Thus, in the present study the positions of appendix and shapes of the caecum were comparable to the study conducted by previous authors. This study also shows that the comparison of position of vermiform appendix and shape of the caecum was statistically not significant.

Table 5: Relation between Shape of Caecum and Position of Appendix

Position of Appendix	Shape of Caecum				Total
	Adult	Exaggerated	Fetal	Infantile	
PELVIC	11	0	2	2	15
PREILEAL	5	4	0	0	9
RETROCAECAL	26	4	1	3	34
POSTILEAL	2	0	0	0	2
Total	44	8	3	5	60
%	73.33	13.33	5.00	8.33	100.00

Test	Degree of freedom	chi-square value	p-value
Chi- Square	9	13.8	0.13

**Graph 2:** Relation between Shape of Caecum and Position of Appendix

4. Conclusion

In human beings due to lack of definition of its true function, the vermiform appendix was considered as a rudimentary and vestigial organ [47]. But if the position, length, outer girth and distance from ileocaecal junction of vermiform appendix are detected, it will help to decrease the complications of appendicular pathology [48]. A thorough knowledge of anatomical shape, length and width of caecum is very necessary for performing various abdominal surgeries [16]. In conclusion, no statistically significant difference was found in the morphology, position and dimensions of appendix and caecum in both the sexes as compared to previous studies.

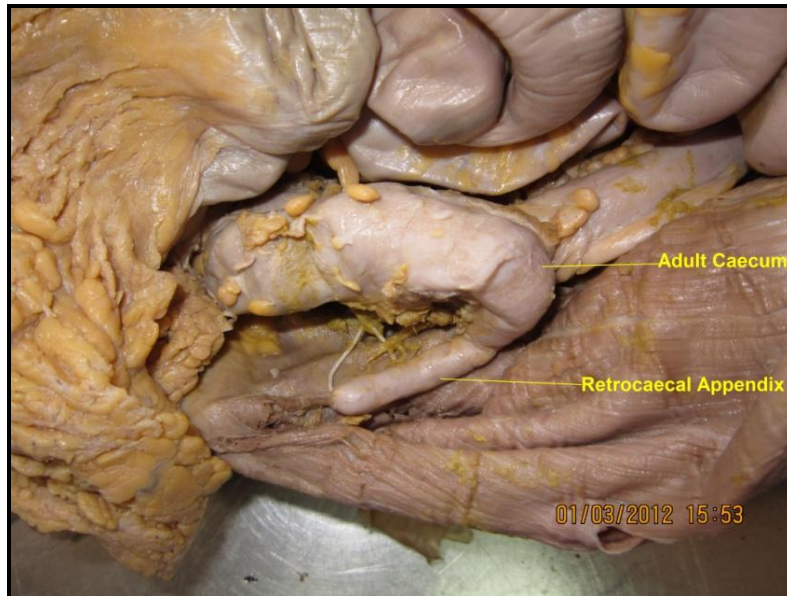


Figure 1: Showing Retrocaecal Appendix with Adult Caecum

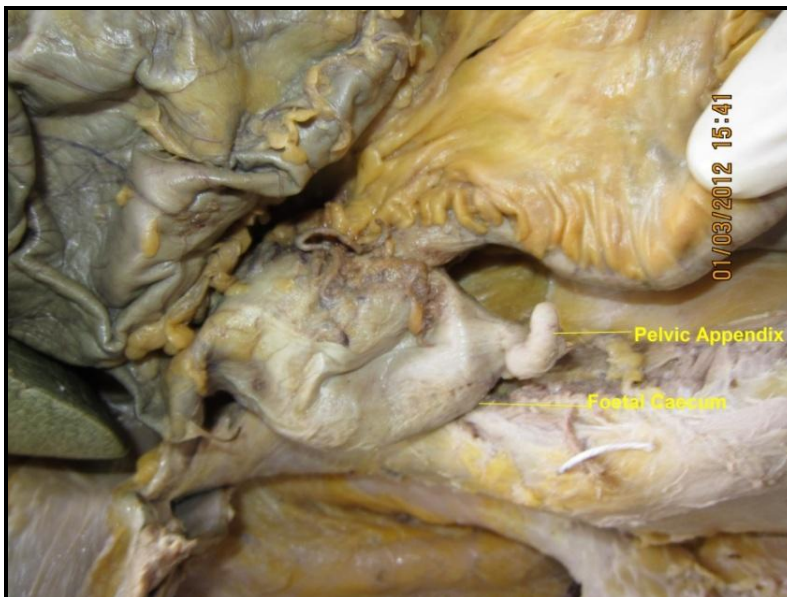

Figure 2: Showing Pelvic Appendix with Foetal Caecum

References

- [1] Tahir Iqbal, Rabnawaz, Asif Iqbal, Farah Tahir and Safeer Zaman. *A Meta-Analysis of History and Functions of Vermiform Appendix*. Pak J Surg. 2011. 27 (4) 316-320.
- [2] Schwartz, S.J., et al. *Principles of Surgery Schwartz*. 7th Ed. Philadelphia: MC Graw-Hill. 1999. 3; 1383-1385.
- [3] Bakheit, M.A., and Warille, A.A. *Anomalies of the Vermiform Appendix and Prevalance of Acute Appendicitis in Khartom*. East African Medical Journal. 1999. 16 (6) 338-340.

- [4] Golalipur, M.J., Arya, B., Azarhoosh, R., and Jahanshahi, M. *Anatomical Variations of Vermiform Appendix in South East Caspian Sea [Gorgoan-Iran]*. J Anat Soc. India. 2003. 52 (2) 141-143.
- [5] Rahman, M.M., Khalil, M., Sultana, S.Z., Mannan, S., Nessa, A., and Ahamed, M.S. *Extent of Mesoappendix in Bangladeshi People*. J Bangladesh Soc. Physiol. 2009. 4 (1) 20-23.
- [6] Sabiston D.C., Townsend and Courtney M. Sabiston's Textbook of Surgery, the Biological Basis of Modern Surgical Practice. 16th Ed. Philadelphia: W.B. Saunders Company. 2001. 2; 918.
- [7] Gray's Anatomy: the Anatomical Basis of Clinical Practice. 2005. 39th Ed. Edinburgh: Elsevier Churchill Livingstone. 1173-1186.
- [8] Solanke, T.F. *The Position, Length and Content of the Vermiform Appendix in Nigerians*. British Journal of Surgery. 1970. 57; 100-102.
- [9] Bhasin, S.K., Khan, A.B., Vijay Sharma, S., and Saraf, R. *Vermiform Appendix and Acute Appendicitis*. JK Science J. 2007. 9 (4) 167-170.
- [10] Buschard, K., Kjaeldgaard, A. *Investigation and Analysis of the Position, Length and Embryology of the Vermiform Appendix*. Acta Chirurgica Scandinavica. 1973. 139 (3) 293-298.
- [11] Paul, U.K., et al. *Position of Vermiform Appendix-A Postmortem Study*. Bangladesh J Anat. 2009 January. 7 (1) 34-36.
- [12] Snell, R.S., 2004: *Clinical Anatomy Baltimore*. 7th Ed. Lippincot William and Wilkins. 215-217.
- [13] Fawcett, D.W., 1994: Bloom and Fawcett: A Text Book of Histology. 12th Ed. New York. 636.
- [14] Wakely, C.P.G. *The Position of the Vermiform Appendix as Described by Analysis of 10,000 Cases*. Journal of Anatomy. 1933. 67; 272.
- [15] Calota, F., et al. *Horseshoe Appendix: An Extremely Rare Anomaly*. Chirurgia. 2010. 105; 271-274.
- [16] Moore, K.L., Persaud, T.V.N., and Torchia, M.G. *The Developing Human: Clinically Oriented Embryology*. 2011. 8th Ed. Philadelphia: Elsevier. 231.
- [17] Glover, J.W. *The Human Vermiform Appendix*. TJ Arch. 1988. 3 (1) 318.
- [18] Herrinton, J.L. Jr. *The Vermiform Appendix: Its Surgical History*. Contemp Surg. 1991. 39; 36-44.
- [19] Tait, L. *Surgical Memoranda. Case of Recurrent Perityphlitis Successfully Treated by Abdominal Section*. Br Med J. 1880. 2; 763-764.
- [20] McBurney, C. *The Incision Made in the Abdominal Wall in Cases of Appendicitis, with a description of a New Method of Operating*. Ann Surg. 1894. 20; 38-43.
- [21] McBurney, C. *Experiences with Early Operative Interference in Cases of Diseases of the vermiform Appendix*. NY Med J. 1889. 50; 676-684, 188.
- [22] Brunton, L. *The Illness of the King (E)*. Br Med J. 1902. 2; 74-75.

- [23] Macphail, S.R. *Note on Length of Vermiform Process in 220 Consecutive Post Mortem Examinations*. J Anat. 1917. 51; 308.
- [24] Collins, D.C. *Diverticula of the Vermiform Appendix: a Study Based On 30 Cases*. Ann. Surg. 1936. 104; 1001.
- [25] Waugh, T.R. *Appendix Vermiforms Duplex*. Arch, Surg. 1941. 42; 311.
- [26] Harsha, W.T. *Retrocaecal Appendix: Its Diagnosis and Surgical Approach*, Surg, Gynaec and Obst. 1942. 74; 180.
- [27] Shah, M.A., and Shah, M. *The Position of Vermiform Appendix*. Ind. Med Gaz. 1945. 8; 494-495.
- [28] Shah, M.A., and Shah, M. *The Arterial Supply of the Vermiform Appendix*. Anat. Rec. 1946. 15; 457-460.
- [29] Pester, G.H. *Congenital Absence of the Vermiform Appendix*. Arch, Surg. 1965. 91; 461.
- [30] Derojas, J.F., and Irons, H.S. Jr. *Diverticulosis of the Appendix*. Arch, Surg. 1968. 96; 429.
- [31] Hollinshead, H.W., 1971: *Anatomy for Surgeons the Thorax, Abdomen and Pelvis*. 2nd Ed. New York: Medical Book Department of Harper and Brothers Publishers. 2; 484-496. 293; 509-510.
- [32] Katzurskj, M.M., Gopalrao, U.K., and Brady, K. *Blood Supply and Position of the Vermiform Appendix in Zambians*. Medical Journal of Zambia. 1979. 13 (2) 32-34.
- [33] Ajmani, M.L., and Ajmani, K. *The Position, Length and Arterial Supply of Vermiform Appendix*. Anatomischer anzeiger. 1983. 153 (4) 369-374.
- [34] Bender Elizabeth and Schmidt S. *Type B2 Appendiceal Duplication with Appendicitis: A Case Report*. Internet J Surg. 2002; 3: 2.
- [35] Delic, J., et al. *Variation in the Position and Point of Origin of the Vermiform Appendix*. Med Art. 2002. 56 (1) 5-8.
- [36] Rahman, M.M., et al. *Anatomical Positions of Vermiform Appendix in Bangladeshi People*. J Bangladesh Soc Physiol. 2006 Dec. 1; 5-9.
- [37] Jorge, A., Ferreira, J.R., and Pacheco, Y.G. *Development of the Vermiform Appendix in Children from Different Age Ranges*. Braz. J. Morphol. Sci. 2009. 26 (2) 68-76.
- [38] Bali, R.S., Wani, M.M., Mir, S.I., Thakur, S., and Bhat, R.A. *Appendiceal Duplication With Simultaneous Acute Appendicitis and Appendicular Perforation Causing Small Bowel Obstruction*. J. Surg. Case Rep. 2011. 2; 3.
- [39] Kulkarni, U.K., and Kulkarni, D.U. *Variations in Arterial Supply of Vermiform Appendix*. International Journal of Anatomical Variations. 2011. 4; 52-54.
- [40] Antic, V., et al. *Morphologic Characteristics of the Vermiform Appendix during the Prenatal Period in Man*. Acta Medica Medianae. 2012. 51 (4) 26-30.

- [41] Sitthichai Vachirasrisirikul. *Length of Appendix and Acute Appendicitis in Adults*. Buddhachinaraj Med J. 2012. 29 (1) 85-90.
- [42] Tahir Iqbal, Amir Amanullah and Rab Nawaz. *Pattern and Positions of Vermiform Appendix in People of Bannu District*. Gomal Journal of Medical Sciences. 2012. 10 (1) 100-103.
- [43] Geethanjali, H.T., and Lakshmi Prabha Subhash. *A Study of Variations in the Position of Vermiform Appendix*. Anatomica Karnataka. 2011. 5 (2) 17-23.
- [44] Sharma Punita, Mahajan Anupama, Verma Poonam and Arora Anterpreet. *Bifid Appendix: Its Embryologic Explanation and Clinical Implications*. Int J Anat Var (IJAV). 2012. 5; 38-40.
- [45] Banerjee A., Kumar I.A., Tapadar A., and Pranay M. *Morphological Variations in the Anatomy of Caecum and Appendix-A Cadaveric Study*. NJCA. 2012. 1 (1) 30-35.
- [46] Mohammad, R., Velichety, S., Thyagaraju, K., Azharuddin, M.D., and Jyothirmayi, K. *Morphological Features and Morphometric Parameters of Human Fetal vermiform Appendix at Different Gestational Ages*. Int J Anat Res. 2013. 1 (2) 18-25.
- [47] Cancado, Jr. apendicite aguda e outras afecções do apendice. Gastroenterologia clínica. 2nd Ed. S.A. Rio de Janeiro: Guanabara Koogan in Dani, R., Castro, L P. 1988. 2; 822-829.
- [48] Rahman, M.M., et al. *Length of Human Vermiform Appendix in Bangladeshi People*. J Bangladesh Soc Physiol. 2007. 2; 13-16.
- [49] Robinson, Arthur, 1923: Cunningham's Text-book of Anatomy. 5th Ed. Edinburgh: William Wood and Co. 1206.
- [50] Kjossev, K.T., and Losanoff, J.E. *Duplicated Vermiform Appendix*. British Journal of Surgery. 1996. 83; 1259.