

## Frontal Bone Cranioplasty

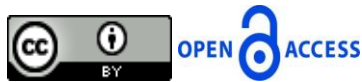Akheel Mohammad

Department of Oral & Maxillofacial Surgery, Dr. NTR University of Health Sciences, Andhra Pradesh, India

Correspondence should be addressed to Akheel Mohammad, drakheelomfs@gmail.com

Publication Date: 6 August 2013

Article Link : <http://medical.cloud-journals.com/index.php/IJADST/article/view/Med-50>



Copyright © 2013 Akheel Mohammad. This is an open access article distributed under the **Creative Commons Attribution License**, which permits unrestricted use, distribution, and reproduction in any medium, provided the original work is properly cited.

**Abstract** Craniofacial skeletal injuries represent one of the most common types of injuries encountered causing long term consequences both functionally and esthetically. Organized protocol has to be followed for Cranioplasty and autogenous bone grafts are more preferred over alloplastic materials. The fractured bone segments can be preserved to reconstruct the bony defects instead of disposing them as done in earlier days. We present here a case that sustained depressed fracture of the frontal bone with multiple facial injuries following a road traffic accident and had undergone frontal bone reconstruction.

**Keywords** *Frontal Bone Fractures, Reconstruction, Craniofacial Injuries*

### 1. Introduction

Frontal bone fractures are most commonly encountered with facial injuries. The anatomy of frontal bone consisting of frontal sinus and their position in maxillofacial skeleton makes it more susceptible for fractures. They are usually accompanied with facial fractures causing disruption at the nasofrontal region. Frontal bone forms the boundary of anterior cranial fossa. The Duramater which is the outermost layer covering the brain is closely adherent to the anterior cranial base. Craniofacial injuries involving the frontal bone breach the duramater and causes CSF leak manifesting itself as CSF rhinorrhoea. Raised intracranial tension, meningitis, meningeal abscess are other complications which can occur if reconstruction of the post traumatic defect is not done. In this article we report a case of faciomaxillary injuries with frontal bone fracture in which reconstruction was done.

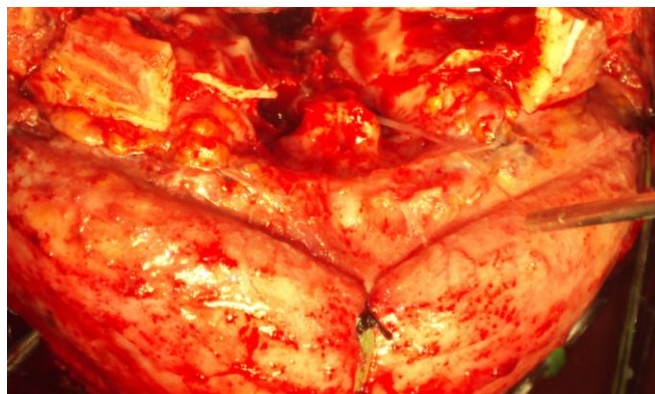
### 2. Case Report

A 46 year old male patient was presented to department of emergency after 5 hours following a road traffic accident. On clinical examination he sustained frontal bone fracture and bilateral zygomatic complex fracture. There was CSF rhinorrhoea. Computed tomography (CT) brain showed oedema of brain, depressed frontal bone fracture with comminuted zygomatic bone fractures. As his Glasgow coma scale (GCS) was low it was planned to operate the patient immediately.

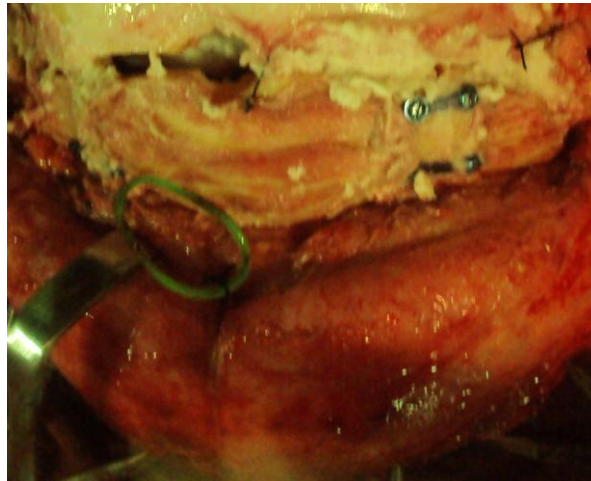
Bicoronal incision was given 3 cm behind the hair line for an inconspicuous scar. Subgaleal dissection was done till the supraorbital rims. The fractured bone segments were collected (Figure 1). Frontal lobe was retracted posteriorly. Pericranial flap was dissected which will act as an artificial duramater and sutured to the duramater of brain on all sides [1]. This technique covers the frontal lobe and provides a seal for it. Tight closure of the duramater was done to prevent Cerebrospinal Fluid (CSF) leakage. The fractured calvarial bone fragments were placed. Mac Ewen et al. [2] in 1888 advocated the use of fractured bony segments which were soaked in bichloride of mercury which was confirmed by other authors recently with satisfactory results [3, 4]. In our case the bone fragment were soaked in povidine-iodine solution and kept over the artificial duramater and fixed with stainless steel miniplates and screws (Figure 2). Hydroxyapatite cement was placed around the bony segments to promote good healing [5]. Haemostasis was achieved. Scalp closure was done in layers. Other facial injuries were reduced and fixed with stainless steel mini plates and screws.

### 3. Discussion

Single stage reconstruction of soft and hard tissues of frontal bone fractures in faciomaxillary injuries poses a great challenge. Often a multidisciplinary team approach is required consisting of maxillofacial surgeon and neurosurgeon. The anatomy of the duramater has to be established to obtain a good anatomical seal of the brain. Coleman et al. [6] in 1942 advocated that the fractured bone fragments have to be removed and discarded if the time of injury is more than 12 hour. The grafts which can be used are pedicled subpericranial grafts and fascia lata. Hard tissue reconstruction has to be done to protect the brain and to establish a good anatomical facial symmetry. Autogenous grafts preferably cancellous bone or calvarial bone grafts [7] are preferred over alloplastic materials like methylmethacrylate and titanium mesh [8, 9]. However infections can occur with autogenous bone grafts in cases of deeply lacerated wounds for a prolonged period from the commencement of primary debridement. Jennet and Miller studied 359 patients with depressed fractures and found 36.5% of infection rate in patients who were treated after 48 hours of injury and 4.6% of postoperative infection rate [4]. Our case was operated within 5 hours and autogenous bone grafts were used which healed well in a follow up period of 6 months. Single stage reconstruction of frontal bone fractures with other maxillofacial injuries is necessary to prevent infections of brain, establish a good facial contour and esthetics of the patient which requires a team approach from a maxillofacial surgeon and a neurosurgeon.



**Figure 1:** *Fractured Frontal Bone*



**Figure 2:** Fixation of Frontal Bone with Stainless Steel Miniplates and Screws. Hydroxyapatite Paste at the Placed Edges of the Fractured Segments

#### 4. Conclusion

Single stage reconstruction of frontal bone can be done by fractured autogenous bone grafts to restore the anatomy as well as esthetics of the patient without requiring any second surgery.

#### References

- [1] Hasegawa M., et al. *Reconstruction of the Anterior Cranial Base with the Galeal Frontalis Myofascial Flap and the Vascularized Outer Table Calvarial Bone Graft*. Neurosurgery. 1995. 36 (4) 725-731.
- [2] MacEwen W. *Address on the Surgery of the Brain and Spinal Cord*. Lancet. 1888. 2; 254-264.
- [3] Braakman R. *Depressed Skull Fracture: Data, Treatment and Follow Up In 225 Consecutive Cases*. J Neurol Neurosurg Psychiat. 1972. 35; 395-402.
- [4] Jennet B., et al. *Infection after Depressed Fracture of Skull: Implications for Management of Non Missile Injuries*. J Neurosurg. 1972. 36; 333-339.
- [5] Chen T.M., et al. *Reconstruction of Post-Traumatic Frontal-Bone Depression Using Hydroxyapatite Cement*. Ann Plast Surg. 2004. 52 (3) 303-30.
- [6] Coleman C. *Treatment of Compound Fractures of the Skull*. Ann Surg. 1942. 115; 506-513.
- [7] Hendus J., et al. *Reconstruction of the Front Orbital Frame Using Split-Thickness Calvarial Bone Grafts*. Laryngorhinootologie. 2005. 84 (12) 899-904.
- [8] Mottaran R., et al. *Reconstruction of a Large Post-Traumatic Cranial Defect with a Customized Titanium Plaque*. J Neurosurg Sci. 2004. 48 (3) 143-147.
- [9] Tuusa S.M., et al. *Frontal Bone Defect Repair with Experimental Glass-Fiber-Reinforced Composite with Bioactive Glass Granule Coating*. J Biomed Mater Res B Appl Biomater. 2007. 82 (1) 149-155.